

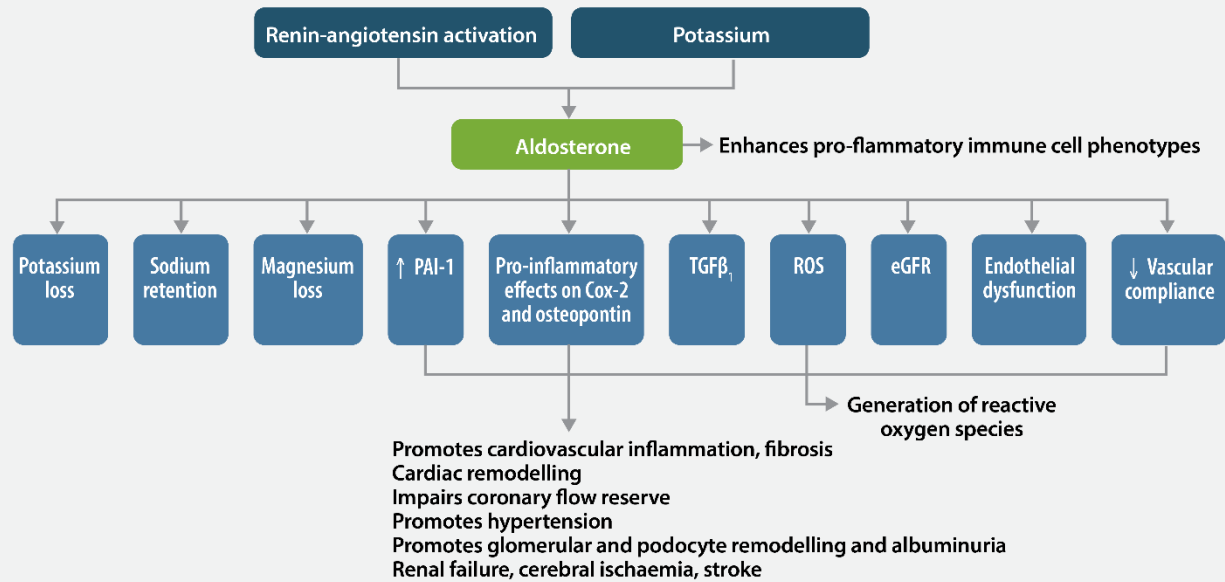


Updates in the Diagnosis & Management of CKD:

Podcast #2 Figures

The Role of Mineralocorticoid Antagonists in Evolving the Therapeutic Landscape

Figure 1. Deleterious Mechanisms of Aldosterone and MR Signaling (Epstein 2015)



Cox-2, cyclooxygenase-2; eGFR, epidermal growth factor receptor; MR, mineralocorticoid receptor; PAI-1, plasminogen activator inhibitor-1; ROS, reactive oxygen species; TGFβ₁, transforming growth factor beta 1. Epstein M. *Lancet Diabetes Endocrinol.* 2015;3(12):993-1003.

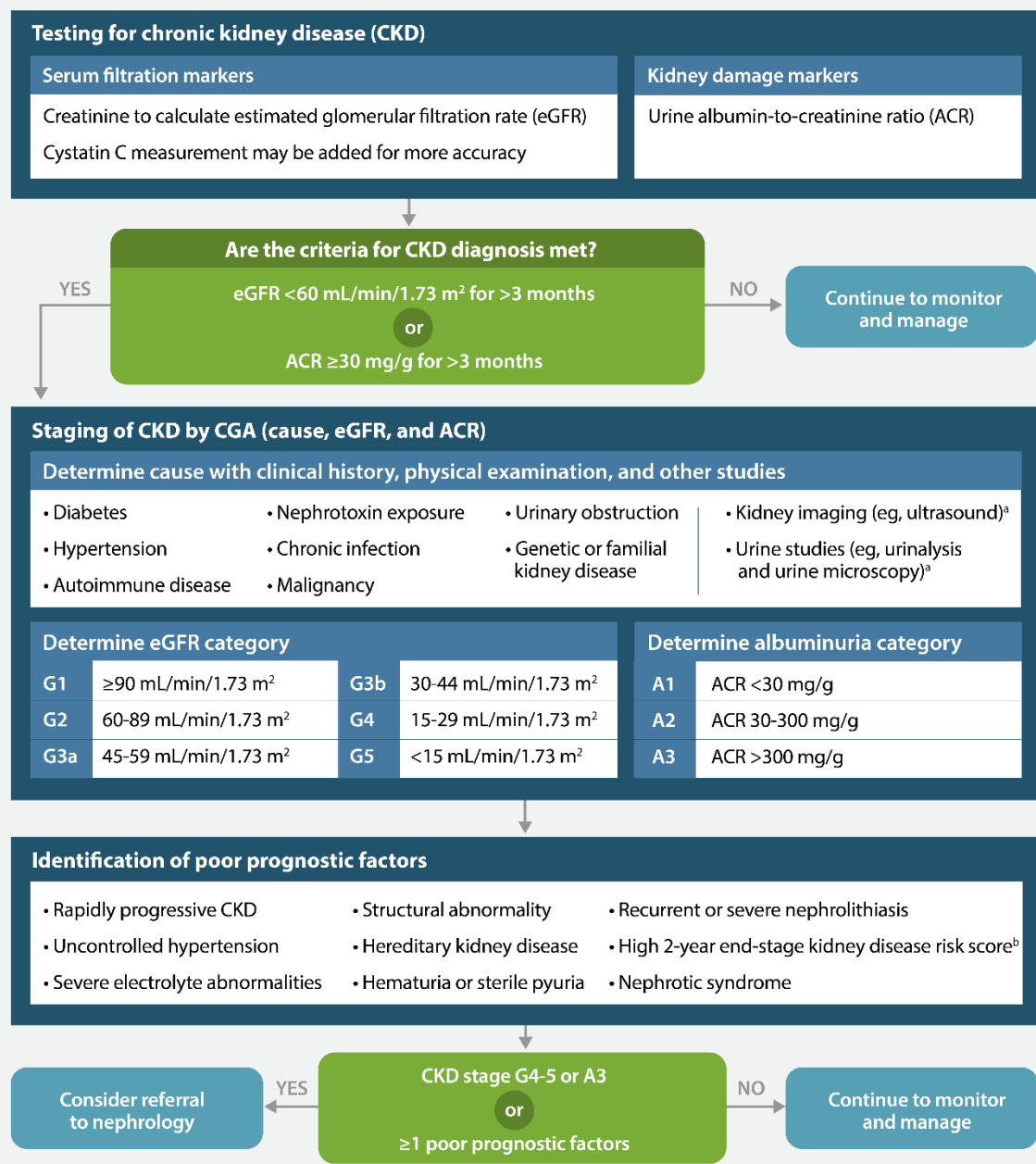


Updates in the Diagnosis & Management of CKD:

The Role of Mineralocorticoid Antagonists in Evolving the Therapeutic Landscape

Podcast #2 Figures

Figure 2. Considerations for Diagnosis, Staging, and Referral of Patients With CKD (Chen 2019)



^a Other imaging modalities or urine studies may also be considered.
^b A variety of scores are available, eg, <https://kidneyfailureliverisk.com/>.
 Chen TK, Knicely DH, Grams ME. *JAMA*. 2019;322(13):1294-1304.